



PRACTICE BULLETIN

CLINICAL MANAGEMENT GUIDELINES FOR OBSTETRICIAN—GYNECOLOGISTS

NUMBER 176, APRIL 2017

(Replaces Committee Opinion Number 513, December 2011)

Pelvic Organ Prolapse

Pelvic organ prolapse (POP) is a common, benign condition in women. For many women it can cause vaginal bulge and pressure, voiding dysfunction, defecatory dysfunction, and sexual dysfunction, which may adversely affect quality of life. Women in the United States have a 13% lifetime risk of undergoing surgery for POP (1). Although POP can occur in younger women, the peak incidence of POP symptoms is in women aged 70–79 years (2). Given the aging population in the United States, it is anticipated that by 2050 the number of women experiencing POP will increase by approximately 50% (3). The purpose of this joint document of the American College of Obstetricians and Gynecologists and the American Urogynecologic Society is to review information on the current understanding of POP in women and to outline guidelines for diagnosis and management that are consistent with the best available scientific evidence.

Background

Definition

Pelvic organ prolapse is the descent of one or more aspects of the vagina and uterus: the anterior vaginal wall, posterior vaginal wall, the uterus (cervix), or the apex of the vagina (vaginal vault or cuff scar after hysterectomy) (4). This allows nearby organs to herniate into the vaginal space, which is commonly referred to as cystocele, rectocele, or enterocele. Mild descent of the pelvic organs is common and should not be considered pathologic. Pelvic organ prolapse only should be considered a problem if it is causing prolapse symptoms (ie, pressure with or without a bulge) or sexual dysfunction or if it is disrupting normal lower urinary tract or bowel function. Pelvic organ prolapse can be defined using patient-reported symptoms or physical examination findings (ie, vaginal bulge protruding to or beyond the hymen). Most women feel symp-

oms of POP when the leading edge reaches 0.5 cm distal to the hymenal ring (5).

Epidemiology

According to the National Health and Nutrition Examination Survey, approximately 3% of women in the United States report symptoms of vaginal bulging (3). In one review, the prevalence of POP based on reported symptoms was much lower (3–6%) than the prevalence identified by examination (41–50%) (6). This discrepancy likely occurs because many women with POP are asymptomatic. Pelvic organ prolapse usually is due to global pelvic floor dysfunction, so most women will present with POP in multiple compartments (anterior, apical, and posterior vaginal wall) (7).

There are few studies of the natural history of POP. In one study that monitored women with symptomatic, untreated POP for an average of 16 months, 78% of the women had no change in the leading edge of the

Committee on Practice Bulletins—Gynecology and American Urogynecologic Society. This Practice Bulletin was developed by the Committee on Practice Bulletins—Gynecology and the American Urogynecologic Society in collaboration with Paul Tulikangas, MD.

The information is designed to aid practitioners in making decisions about appropriate obstetric and gynecologic care. These guidelines should not be construed as dictating an exclusive course of treatment or procedure. Variations in practice may be warranted based on the needs of the individual patient, resources, and limitations unique to the institution or type of practice.



prolapse (8). Most of the women had stage II–IV pelvic organ prolapse (Box 1). In women who do not want treatment for their POP, most will have no change or only a small increase in the size of the POP over the next year (9).

The incidence of POP surgery is 1.5–1.8 surgeries per 1,000 women years (10, 11). There are approximately 300,000 POP surgeries each year in the United States (12).

Risk Factors

Risk factors for developing symptomatic POP include parity, vaginal delivery, age, obesity, connective tissue disorders, menopausal status, and chronic constipation (13–17). Modifiable risk factors (obesity and constipation) should be addressed in patients at wellness visits because improvement in these factors may reduce the risk of developing POP.

It is not clear if hysterectomy for non-POP conditions is a risk factor for developing POP. In a subanalysis of a cohort study from the United Kingdom, patients who underwent a hysterectomy had a 5% cumulative risk of undergoing prolapse surgery within the next 15 years (13). A more recent study found no increased risk of POP in women who underwent prior hysterectomy for non-POP indications (18).

Box 1. Stages of Pelvic Organ Prolapse ◀

Stages are based on the maximal extent of prolapse relative to the hymen, in one or more compartments.

Stage 0: No prolapse; anterior and posterior points are all -3 cm, and C or D is between $-TVL$ and $-(TVL - 2)$ cm.

Stage I: The criteria for stage 0 are not met, and the most distal prolapse is more than 1 cm above the level of the hymen (less than -1 cm).

Stage II: The most distal prolapse is between 1 cm above and 1 cm below the hymen (at least one point is -1 , 0, or $+1$).

Stage III: The most distal prolapse is more than 1 cm below the hymen but no further than 2 cm less than TVL.

Stage IV: Represents complete procidentia or vault eversion; the most distal prolapse protrudes to at least $(TVL - 2)$ cm.

Abbreviations: C, cervix; D, posterior fornix; TVL, total vaginal length. Adapted from Bump RC, Mattiasson A, Bo K, Brubaker LP, DeLancey JO, Klarskov P, et al. The standardization of terminology of female pelvic organ prolapse and pelvic floor dysfunction. *Am J Obstet Gynecol* 1996;175:10–7.

Older studies reported that women who underwent primary POP surgery had an approximate 30–50% chance of needing a second prolapse surgery (19). More recent studies show a lower reoperation rate of approximately 6–30%, with most estimates consistent with the lower end of this range (19–22). This lower reoperation rate may reflect improvement in surgical technique as well as stratification of urinary incontinence as a separate risk in the outcomes data (19). Pelvic organ prolapse surgery that includes suspension of the vaginal apex is associated with a decreased reoperation rate (23). Risk factors for recurrent prolapse include age younger than 60 years for patients who underwent vaginal surgery for POP, obesity, and preoperative stage III or stage IV prolapse (24–26).

Clinical Considerations and Recommendations

► *What is the recommended initial evaluation for a woman with suspected pelvic organ prolapse?*

The recommended initial evaluation for a woman with suspected POP includes a thorough history, assessment of symptom severity, physical examination, and goals for treatment. Symptom assessment is the most important part of the evaluation of a woman with POP.

History

In addition to a complete medical, surgical, obstetric, and gynecologic history, the nature of vaginal bulge symptoms and the degree of bother associated with the bulge should be recorded. Key information to elicit from the patient includes whether the protrusion is limiting physical activities or sexual function or becoming progressively worse or bothersome. Many women with POP on physical examination do not report symptoms of POP. Treatment is indicated only if prolapse is causing bothersome bulge and pressure symptoms, sexual dysfunction, lower urinary tract dysfunction, or defecatory dysfunction (27).

Lower urinary tract function should be assessed. This includes an evaluation for urine loss and type (stress or urgency urinary incontinence) and adequacy of bladder emptying. The relationship between urinary symptoms and prolapse can be inferred if voiding becomes more difficult when the effects of gravity are more pronounced, such as after long periods of standing (4). In addition, splinting (ie, the need to push on or support the bulging tissue) may be required to initiate or complete voiding.



Assessment of bowel function should be undertaken to determine if there is a history of straining with bowel movements, laxative use, fecal incontinence, and incomplete rectal emptying. The symptom of splinting often is correlated with the presence of a posterior compartment defect (eg, rectocele). Each patient should be assessed for symptoms of dyspareunia, coital incontinence (of urine or stool), and sexual dysfunction that is related to the prolapse.

Physical Examination

Physical examination should include an abdominal and pelvic examination to rule out pelvic masses. The external genitalia and vaginal epithelium should be evaluated for vaginal atrophy, skin irritation, or ulceration (27). Simply spreading the labia while examining the patient in a supine position can be helpful to assess the maximum descent of the prolapse. A detailed examination of the POP should be performed with a split speculum (ie, separate a bivalve speculum and use only the posterior blade to examine the apex and anterior vaginal wall, then turn the blade over and use it to hold the anterior wall while examining the postvaginal wall and perineal body as the patient performs the Valsalva maneuver, repetitive coughing, or both). Performance of a pelvic organ prolapse quantification (POP-Q) examination is recommended before treatment for the objective evaluation and documentation of the extent of prolapse (see *Is the pelvic organ prolapse quantification examination necessary before treatment for pelvic organ prolapse?*) If a patient's prolapse symptoms are not confirmed by the extent of prolapse observed during supine pelvic examination, repeating the pelvic examination in the standing position may reveal the greatest descent of POP.

Pelvic floor muscle tone should be assessed (27). It should be noted if the pelvic floor muscles can contract and relax volitionally. The strength of the contraction should be described as “absent,” “weak,” “normal,” or “strong” (4).

► Is additional testing beyond history and physical examination needed to evaluate women with pelvic organ prolapse?

In general, no additional testing beyond a complete gynecologic, urologic, and defecatory history and physical examination is needed before treatment. However, if the prolapse is beyond the hymen or the patient has voiding symptoms, a postvoid residual urine volume should be recorded either with a catheter or ultrasonography (27). If there is urinary urgency or other lower urinary tract symptoms, minimum assessment involves

a urinalysis, with culture and microscopy performed if indicated. Urodynamic testing may help inform patient counseling and may be considered if there is bothersome incontinence with stage II or greater prolapse or voiding dysfunction. If findings on initial assessment do not concur with symptoms, more specific imaging or referral to a specialist in urogynecologic care may be needed.

► Is the pelvic organ prolapse quantification examination necessary before treatment of pelvic organ prolapse?

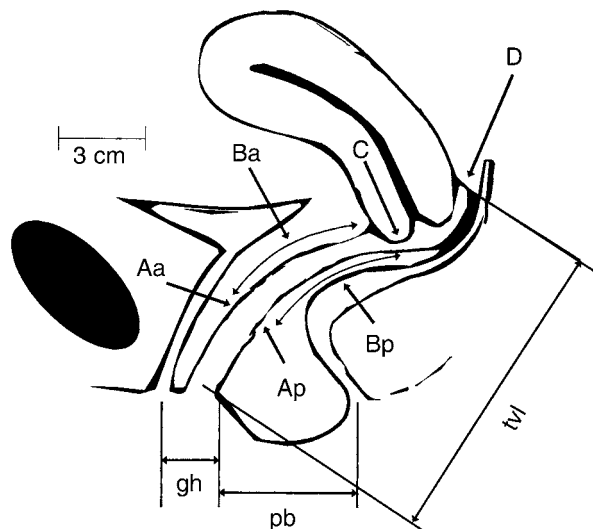
A POP-Q examination is recommended before treatment of POP to objectively evaluate and document the extent of prolapse. Evaluation and documentation of the extent of the prolapse is important before treatment so that the surgeon has a preoperative comparator by which to measure postoperative anatomic success. The POP-Q system is the only validated method for objective measurement of prolapse in the three pelvic compartments: 1) anterior, 2) apical, and 3) posterior (Fig. 1) (28–30). The POP-Q system is recommended by the major national and international urogynecologic health organizations, including the American Urogynecologic Society, the Society of Gynecologic Surgeons, and the International Continence Society (31). In addition, POP-Q is used in most scientific publications on POP (32). Although the Baden–Walker system clinically describes prolapse findings, the POP-Q system is more precise and has been shown to be reproducible.

The POP-Q system does not use the terms “cystocele” and “rectocele” but instead uses terms for each prolapsed segment because the exact organ that lies behind the prolapsed vaginal epithelium may not be clear from the clinical examination. It incorporates measurements of the vaginal length, genital hiatus, and perineal body. The POP-Q measurements can be converted to stages based on the most severely prolapsed vaginal segment (Box 1) (28).

A validated examination allows for consistency in reporting and facilitates communication between gynecologic care providers. It is particularly important if a patient has a recurrent prolapse because it will allow a new gynecologic care provider to understand the patient's POP history. Outcomes can be evaluated only if pretreatment POP measurements are recorded accurately.

For patients desiring expectant management, documentation of the prolapse with the POP-Q allows an objective, validated, baseline measurement that can be referred to if symptoms change over time. Although recording a POP-Q examination is not necessary for





Anterior wall	Anterior wall	Cervix or cuff
Aa	Ba	C
Genital hiatus	Perineal body	Total vaginal length
gh	pb	tvl
Posterior wall	Posterior wall	Posterior fornix
Ap	Bp	D

Figure 1. ⇐ Pelvic organ prolapse quantification system. Nine defined points measured in the midline and relative to the hymen assessed during maximal Valsalva except for TVL: Aa, 3 cm proximal to the external urethral meatus; Ba, most prolapsed portion of the anterior vaginal wall; C, leading edge of the cervix or vaginal cuff; gh, middle of the urethral meatus to the midline of the posterior hymen; pb, middle of the posterior hymen to the middle of the anal opening; tvl, maximum depth of the vagina with prolapse reduced; Ap, 3 cm proximal to the posterior hymen; Bp, most prolapsed portion of the posterior vaginal wall; D, posterior fornix in a woman who has a cervix. (Reprinted with permission from Bump RC, Mattiasson A, Bo K, Brubaker LP, DeLancey JO, Klarskov P, et al. The standardization of terminology of female pelvic organ prolapse and pelvic floor dysfunction. *Am J Obstet Gynecol* 1996;175:10–17.)

these patients, it may be helpful to determine if there is an anatomic change over time.

► **Are effective nonsurgical treatments available for women with pelvic organ prolapse?**

For women with asymptomatic prolapse, education and reassurance are appropriate. Women may not realize that symptoms of voiding or defecatory dysfunction are related to prolapse, so education about how prolapse symptoms manifest can be helpful.

Some symptoms related to pelvic organ prolapse may be managed with lifestyle modifications. For example, defecatory dysfunction may improve with fiber supplementation and use of an osmotic laxative (33). Sitting with feet elevated may decrease bulge symptoms. Pelvic muscle exercises, performed either independently or under professional supervision may improve symptoms or slow the progression of POP (34, 35).

There is limited evidence for the treatment or prevention of POP with local or systemic estrogen (36). However, some clinicians believe that local estrogen may help with the vaginal irritation associated with POP.

Women considering treatment of POP should be offered a vaginal pessary as an alternative to surgery. A pessary should be considered for a woman with symptomatic POP who wishes to become pregnant in

the future. A vaginal pessary is an effective nonsurgical treatment for women with POP, and up to 92% of women can be fitted successfully with a pessary (37). In one study protocol, a ring pessary was inserted first, followed by a Gellhorn pessary if the ring did not stay in place. Ring pessaries were used more successfully with stage II (100%) and stage III (71%) prolapse, and stage IV prolapse more frequently required Gellhorn pessaries (64%) (38). If possible, women should be taught to change their pessary independently. If a woman is unable to remove and replace her pessary, regular follow-up (such as every 3–4 months) is necessary. Annual follow-up is recommended for patients who are able to maintain pessary hygiene on their own.

Pressure on the vaginal wall from the pessary may result in local devascularization or erosion in 2–9% of patients (39). Therapy should consist of removing the pessary for 2–4 weeks and local estrogen therapy. Resolution may occur without local estrogen therapy. If the problems persist, more frequent pessary changes or a different pessary may be required (39). Caregivers to patients with dementia should be made aware of the regular pessary changes needed to avoid complications. Although rare complications such as fistula can occur, pessary use is a low-risk intervention that can be offered to all women who are considering treatment of POP (40).



► **When is surgery indicated for the management of pelvic organ prolapse, and what are the primary approaches?**

Surgery is indicated for the treatment of POP in women who are bothered by their POP and have failed or declined nonsurgical treatments. There are various vaginal and abdominal surgical approaches for the treatment of POP (Table 1). Important considerations for deciding the type and route of surgery include the location and severity of prolapse, the nature of the symptoms (eg, presence of urinary, bowel, or sexual dysfunction), the patient's general health, patient preference, and the surgeon's expertise (41).

► **Are vaginal surgical approaches effective for the management of pelvic organ prolapse?**

Vaginal hysterectomy and vaginal apex suspension with vaginal repair of anterior and posterior vaginal wall prolapse as needed are effective treatments for most women with uterovaginal and anterior and posterior vaginal wall prolapse (21, 22, 42, 43). Vaginal native tissue repairs are performed without the use of synthetic mesh or graft materials. These are relatively low-risk surgeries that may be considered as surgical options for most women with primary POP.

If a patient has uterine prolapse, vaginal hysterectomy alone is not adequate treatment. Vaginal apex suspension should be performed at the time of hysterectomy for uterine prolapse to reduce the risk of recurrent POP (23, 44). Vaginal apex suspension involves attachment of the vaginal apex to the uterosacral ligaments or

sacrospinous ligaments. Uterosacral and sacrospinous ligament suspension for apical POP with native tissue are equally effective surgical treatments of POP, with comparable anatomic, functional, and adverse outcomes (21). In the Operations and Pelvic Muscle Training in the Management of Apical Support Loss trial, the 2-year follow-up surgical success rate was 64.5% for uterosacral ligament suspension compared with 63.1% for sacrospinous ligament fixation (adjusted odds ratio [OR], 1.1; 95% confidence interval [CI], 0.7–1.7) (21). The serious adverse event rate at 2-year follow-up was 16.5% for uterosacral ligament suspension compared with 16.7% for sacrospinous ligament fixation (adjusted OR, 0.9; 95% CI, 0.5–1.6) (21). Uterosacral ligament suspension can be performed by attaching the vaginal apex bilaterally to the ipsilateral uterosacral ligament or by attaching the vaginal apex to uterosacral ligament complex that is plicated in the midline (42, 43, 45). It is important that an adequate segment of uterosacral ligament is secured to the vagina. This often requires attachment to the midportion of the uterosacral ligament close to the ischial spine. Alternatively, the sacrospinous ligament can be used to support the vaginal apex. A unilateral right sacrospinous ligament fixation usually is used for the attachment point to avoid dissection around the colon (46).

Anterior colporrhaphy is an effective treatment for most anterior vaginal wall prolapse (47). Many women with anterior vaginal wall prolapse also have an apical prolapse (48). In these women, surgery should correct the apical prolapse and the anterior vaginal wall prolapse. Resupport of the vaginal apex concurrently with repair of the anterior vaginal wall

Table 1. Types of Pelvic Organ Prolapse Surgery ↵

Surgical Technique	Aim	Indication
Abdominal sacral colpopexy	To correct upper vaginal prolapse	Most commonly used in women with recurrent cystocele, vault, or enterocele
Uterosacral ligament suspension	To correct upper vaginal prolapse	Performed at the time of hysterectomy or in patients with posthysterectomy vaginal vault prolapse
Sacrospinous fixation	To correct upper vaginal prolapse	Performed at the time of hysterectomy or in patients with posthysterectomy vaginal vault prolapse
Anterior vaginal repair (anterior colporrhaphy)	To correct anterior wall prolapse	May be used for the treatment of prolapse of the bladder or urethra (bladder, urethra, or both herniate downward into the vagina)
Posterior vaginal repair (posterior colporrhaphy) and perineorrhaphy	To correct posterior wall prolapse	May be used for the treatment of rectocele (rectum bulges or herniates forward into the vagina), defects of the perineum, or both
Vaginal repair with synthetic mesh or biologic graft augmentation	To correct anterior wall prolapse, apical vaginal prolapse, or both	Depending on the specific defect, the mesh augmentation can either be anterior, apical, or both. This repair is not routinely recommended.

Adapted from Maher C, Feiner B, Baessler K, Christmann-Schmid C, Haya N, Marjoribanks J. Transvaginal mesh or grafts compared with native tissue repair for vaginal prolapse. *Cochrane Database Syst Rev* 2016 Feb 9;2:CD012079.



defect reduces the risk of recurrent POP surgery (23). Paravaginal defects are lateral detachments of the vaginal wall from the fascial condensations over the levator ani muscles (49, 50). Diagnosis of paravaginal defects by physical examination is unreliable (51, 52). Moreover, if a paravaginal defect is suspected, there usually is apical loss of support (50). Apical support procedures may address most anterior vaginal wall defects, including paravaginal defects (53).

Posterior vaginal wall repair traditionally has been performed through a midline plication of the posterior vaginal wall fibromuscular connective tissue (54). The repair should be performed without placing tension on the levator ani muscles because this may lead to dyspareunia (55). Perineorrhaphy that results in reattachment of the perineal muscles to the rectovaginal septum can be performed as needed if a perineal defect is present. An alternative technique for performing posterior vaginal wall repair is site-specific repair, which involves dissection of the vaginal epithelium off the underlying fibromuscular connective tissue and repair of localized tissue defects with sutures. A finger often is placed in the rectum and directed anteriorly to identify various tissue defects of the posterior vaginal wall (56). Although a retrospective comparison of site-specific repair and midline colporrhaphy found that site-specific repair was associated with a higher rate of recurrence of a symptomatic bulge (11% versus 4%, $P=.02$) (57), a prospective study showed comparable outcomes for the two techniques (58).

► *When is abdominal sacrocolpopexy indicated for the management of pelvic organ prolapse?*

Abdominal sacrocolpopexy is a proven and effective surgery for the treatment of POP (20, 59). This procedure involves placement of a synthetic mesh or biologic graft from the apex of the vagina to the anterior longitudinal ligament of the sacrum. Women who may be candidates for abdominal sacrocolpopexy include those who have a shortened vaginal length, intra-abdominal pathology, or risk factors for recurrent POP (eg, age younger than 60 years, stage 3 or 4 prolapse, and body mass index greater than 26) (24–26). In women who are at increased risk of synthetic mesh-related complications (eg, chronic steroid use, current smoker), sacrocolpopexy with a biologic graft or alternatives to a sacrocolpopexy could be considered.

Studies evaluating abdominal sacrocolpopexy with biologic grafts show conflicting results. Abdominal sacrocolpopexy with porcine dermis xenograft had efficacy similar to that of abdominal sacrocolpopexy with synthetic polypropylene mesh. However, the por-

cine dermal xenograft used in this study is no longer available (60). In a study that evaluated the 5-year surgical outcomes of abdominal sacrocolpopexy among patients randomized to receive polypropylene mesh or cadaveric fascia lata, use of synthetic mesh resulted in better anatomic cure than use of cadaveric fascia lata grafts (93% [27 out of 29] versus 62% [18 out of 29], $P=.02$) (61).

Abdominal sacrocolpopexy with synthetic mesh has a lower risk of recurrent POP but is associated with more complications than vaginal apex repair with native tissue. Data from randomized controlled trials also show a significantly greater likelihood of anatomic success with mesh abdominal sacrocolpopexy compared with vaginal apex repair with native tissue (pooled OR, 2.04; 95% CI, 1.12–3.72) (62). Surgical complications that are more common after abdominal sacrocolpopexy with mesh include ileus or small-bowel obstruction (2.7% versus 0.2%, $P<.01$), thromboembolic phenomena (0.6% versus 0.1%, $P=.03$), and mesh or suture complications (4.2% versus 0.04%, $P<.01$) (62). In addition, sacrocolpopexy with mesh is associated with a significant reoperation rate due to mesh-related complications. Long-term (ie, 7-year) follow-up of participants of the Colpopexy and Urinary Reduction Efforts (CARE) trial found that the estimated rate of mesh complications (erosion into the vagina, visceral erosions, and sacral osteitis) was 10.5% (95% CI, 6.8–16.1), with a significant number of reoperations (20). Many of the CARE trial sacrocolpopexies, however, were performed with non-type 1 mesh, which may have increased the mesh complication rate. Because of complications attributed to multifilament and small-pore-size synthetic mesh, type 1 synthetic meshes (monofilament with large pore size) currently are used in the United States.

► *Do patients benefit from a minimally invasive approach to pelvic organ prolapse surgery?*

Sacrocolpopexy with or without supracervical hysterectomy or total hysterectomy can be performed laparoscopically with or without robotic assistance (63). Although open abdominal sacrocolpopexy is associated with shorter operative times (222 minutes versus 296 minutes; $P<.02$), minimally invasive sacrocolpopexy is associated with less blood loss (122 ± 146 mL versus 187 ± 142 mL; $P<.01$) and shorter hospitalization (1.3 ± 1 days versus 2.9 ± 1.6 days; $P<.01$) (64). Similar results were seen in a randomized controlled trial that compared open abdominal sacrocolpopexy with laparoscopic sacrocolpopexy, in which mean blood loss was significantly greater in the open arm (mean difference [MD] 184 mL; 95% CI, 96–272), and there were fewer



inpatient days in the laparoscopic group (MD, 0.9 days; 95% CI, 0.1–1.7) (65).

Although robotic assistance shortens the learning curve for performing laparoscopic sacrocolpopexy and improves surgeon ergonomics (66–68), it has not been shown to improve short-term outcomes for patients (69–72). In two randomized controlled trials that compared robot-assisted sacrocolpopexy with laparoscopic sacrocolpopexy, operating time, postoperative pain, and cost were found to be significantly greater in the robot-assisted group (69, 72). The groups had similar anatomic and functional outcomes 6 months to 1 year after surgery, although the robotic experience of the surgeons was low at the start of the study, which may have affected the results (73). Overall, the current literature is too scant to adequately indicate which minimally invasive approach should be recommended. Further comparative studies that assess long-term anatomic and functional outcomes and patient safety and that identify subgroups of patients who would benefit from a robotic approach are warranted (74).

► ***Is posterior vaginal wall prolapse repair more effective with a transanal or transvaginal incision?***

Posterior vaginal wall prolapse repair is more effective when performed through a transvaginal incision than a transanal incision. Systematic review findings show that, compared with transanal incision, posterior vaginal repair results in fewer recurrent prolapse symptoms (relative risk [RR], 0.4; 95% CI, 0.2–1.0), lower recurrence on clinical examination (RR, 0.2; 95% CI, 0.1–0.6), and a smaller mean depth of rectocele on postoperative defecography (MD, –1.2 cm; 95% CI, –2.0 to –0.3) (75).

► ***Are surgical approaches available to treat pelvic organ prolapse in women with medical comorbidities?***

Obliterative procedures—which narrow, shorten, or completely close the vagina—are effective for the treatment of POP and should be considered a first-line surgical treatment for women with significant medical comorbidities who do not desire future vaginal intercourse or vaginal preservation (76–79). Obliterative procedures have high reported rates of objective and subjective improvement of POP (98% and 90%, respectively) (80) and are associated with a low risk of recurrent POP (76, 80, 81). Because obliterative surgical procedures can be performed under local or regional anesthesia, these procedures may be especially beneficial for the treatment of POP in women with significant medical comorbidities that preclude general anesthesia or prolonged surgery,

such as cardiac disease, chronic obstructive pulmonary disease, or thromboembolic disease. In addition, obliterative procedures for the treatment of POP are associated with low rates of complications, intensive care unit admissions, and mortality (6.8%, 2.8%, and 0.15%, respectively) (82). Patients undergoing obliterative procedures must be committed to no longer having vaginal sexual intercourse. In a multisite prospective study of older women (mean age 79 years) who underwent obliterative repair of POP, 95% of patients (125 out of 132) reported being satisfied or very satisfied with the results of the procedure 1 year after surgery (79). Patient regret also has been reported to be low. Among women interviewed more than 1 year after obliterative prolapse repair, only 9% (3 out of 32) reported they regretted having the procedure (81).

Common types of obliterative surgical repair of POP include a Le Fort-style partial colpocleisis and total colectomy. Le Fort partial colpocleisis is performed when the uterus is preserved at the time of prolapse repair. This procedure involves denuding a strip of epithelium from the anterior and posterior vaginal walls and then suturing them together (83). This leaves lateral canals to drain the secretions from the cervix. Because the uterus is difficult to access postoperatively, normal results from cervical cytology and human papillomavirus testing and an endometrial evaluation usually are documented before surgery. For posthysterectomy vaginal prolapse, a colectomy or tight anterior and posterior colporrhaphy creating a constricted vagina is a surgical option if a patient is amenable to an obliterative procedure. In total colectomy procedures, the entire vaginal epithelium is denuded and sutures are used to invert the vagina (83). With any obliterative procedure, a suburethral plication or midurethral sling and a perineorrhaphy often are recommended to decrease the risk of postoperative stress urinary incontinence and recurrent posterior vaginal wall prolapse (80).

► ***What can be recommended regarding currently available synthetic mesh and biologic graft materials for use in vaginal pelvic organ prolapse surgery?***

The use of synthetic mesh or biologic grafts in POP surgery is associated with unique complications not seen in POP repair with native tissue. A systematic review of seven randomized controlled trials that compared native tissue repair with synthetic mesh vaginal prolapse repair found that more women in the mesh group required repeat surgery for the combined outcome of prolapse, stress incontinence, or mesh exposure (RR, 2.40; 95% CI, 1.51–3.81) (41). The rate of mesh exposure



was 12%, and 8% of women required repeat surgery for mesh exposure up to 3 years after the initial surgery (41). Systematic review findings show that vaginal repair of prolapse with biologic grafts (tissue from human cadaver or other species) results in similar rates of “awareness of prolapse” and reoperation for prolapse compared with repairs using native tissue (41). However, it is difficult to make an overall recommendation about the use of biologic grafts for vaginal prolapse repair because the available evidence is of low quality, and most of the biologic grafts that were used in studies to date are no longer available.

Synthetic mesh placed through a transvaginal incision to correct POP has been studied extensively, although there are few long-term (greater than 3 years) studies regarding the effectiveness of procedures currently being performed, as many transvaginal mesh products were removed from the market following the 2011 U.S. Food and Drug Administration (FDA) announcement that identified serious safety and effectiveness concerns over the use of transvaginal mesh to treat POP (84). In January 2016, the FDA issued two final orders regarding surgical mesh that is used to repair POP transvaginally (85):

1. The FDA reclassified this surgical mesh—from class II, which generally includes moderate-risk devices, to class III, which generally includes high-risk devices.
2. The FDA required manufacturers to submit a premarket approval application to support the safety and effectiveness of surgical mesh for the transvaginal repair of POP.

Subsequently, in January 2017, the FDA reclassified all urogynecologic surgical mesh instrumentation (whether used for transvaginal POP repair or other urogynecologic surgical mesh procedures) from class I (low risk) exempt from premarket notification to class II (moderate risk) and subject to premarket notification (86).

Posterior Vaginal Repair

The use of synthetic mesh or biologic grafts in transvaginal repair of posterior vaginal wall prolapse does not improve outcomes (41). In addition, there are increased complications (eg, mesh exposure) associated with placement of mesh through a posterior vaginal wall incision (54). In two randomized trials that compared native tissue with biologic graft material for the repair of posterior prolapse, the objective failure rate was significantly lower at the 1-year follow up in the native tissue group (10% [10 out of 98]) as compared with the biologic graft group (21% [20 out of 93]) (RR, 0.47; 95% CI, 0.24–0.94), and the subjective failure rate was similar

between the groups (RR, 1.09; 95% CI, 0.45–2.62) (58, 75, 87). There was no difference in the rate of postoperative dyspareunia between the groups (RR, 1.26; 95% CI, 0.59–2.68). Another trial that compared posterior biologic graft repair with traditional repair noted worse anatomic outcomes with posterior biologic graft repair than with traditional repair (46% versus 14%; $P=0.02$) (19, 58). Thus, synthetic mesh or biologic grafts should not be placed routinely through posterior vaginal wall incisions to correct POP for primary repair of posterior vaginal wall prolapse.

Anterior Vaginal Repair

Polypropylene mesh augmentation of anterior vaginal wall prolapse repair improves anatomic and some subjective outcomes but does not affect reoperation rates for recurrent prolapse and is associated with a higher rate of complications compared with native tissue vaginal prolapse repair (41). Polypropylene mesh grafts placed through anterior vaginal wall incisions improve subjective outcomes and the anatomic success rates for repair of anterior vaginal wall defects compared with native tissue repair (88, 89). However, vaginally placed polypropylene mesh is associated with longer operating times and greater blood loss compared with native tissue anterior repair (88, 90). The use of vaginally placed polypropylene mesh does not decrease the chance of having a repeat surgery for POP and may lead to surgeries to correct mesh-related complications.

Pelvic organ prolapse vaginal mesh repair should be limited to high-risk individuals in whom the benefit of mesh placement may justify the risk, such as individuals with recurrent prolapse (particularly of the anterior or apical compartments) or with medical comorbidities that preclude more invasive and lengthier open and endoscopic procedures. Before placement of synthetic mesh grafts in the anterior vaginal wall, patients should provide their informed consent after reviewing the benefits and risks of the procedure and discussing alternative repairs. For more information, see Committee Opinion No. 694, *Management of Mesh and Graft Complications in Gynecologic Surgery*.

► Is special training required to perform pelvic organ prolapse procedures that use mesh or biologic grafts?

Surgeons who perform POP surgery with biologic grafts or synthetic mesh grafts should have training specifically for these procedures and should be able to counsel patients regarding the risk–benefit ratio for the use of mesh compared with native tissue repair. There are unique risks and complications associated



with the use of mesh in surgeries to treat POP. Special training regarding patient selection, anatomy, surgical technique, postoperative care, and management of complications is necessary for physicians who perform POP surgery using mesh or biologic grafts (84, 90, 91). The American Urogynecologic Society has published guidelines for training and privileging for the performance of abdominal sacrocolpopexy and vaginal mesh prolapse surgery (92, 93).

► ***Is it necessary to perform intraoperative cystoscopy during pelvic organ prolapse surgery?***

Routine intraoperative cystoscopy during POP surgery is recommended when the surgical procedure performed is associated with a significant risk of injury to the bladder or ureter. These procedures include suspension of the vaginal apex to the uterosacral ligaments, sacrocolpopexy, and anterior colporrhaphy and the placement of mesh in the anterior and apical compartments (94, 95).

Intraoperative cystoscopy is performed after completion of POP repair while the patient is still under anesthesia and should include a complete survey of the bladder and assessment of efflux of urine from the ureteral orifices. Identified issues such as no flow or reduced flow from the ureter or an injury to the bladder should be addressed intraoperatively. Delay in recognition of a urinary tract injury may lead to increased morbidity (96).

► ***Are there effective pelvic organ prolapse surgical treatment methods available for women who prefer to avoid hysterectomy?***

Women who desire surgical treatment of POP may choose to avoid hysterectomy for a variety of reasons, including preservation of fertility, maintenance of body image, and beliefs about adverse effects on sexual function (97–99). Alternatives to hysterectomy for the surgical treatment of POP include hysteropexy (ie, uterine suspension) and Le Fort colpocleisis.

Hysteropexy

Hysteropexy is a viable alternative to hysterectomy in women with uterine prolapse, although there is less available evidence on safety and efficacy compared with hysterectomy (99). Hysteropexy may be performed through a vaginal incision by attaching the cervix to the sacrospinous ligament with sutures (100) or mesh (101). Hysteropexy also may be performed abdominally or laparoscopically by placing a mesh or biologic graft from the cervix to the anterior longitudinal ligament (99). Shortening the uterosacral ligaments laparoscopically with or without robotic assistance or by an abdominal

incision also can be performed. A 2016 cohort study that compared laparoscopic sacral hysteropexy with vaginal mesh hysteropexy found that, at 1-year follow-up, the two procedures had similar efficacy and no significant differences in the rate of complications, blood loss, or length of hospitalization (101).

Benefits of hysteropexy compared with total hysterectomy include shorter operative time and a lower incidence of mesh erosion if mesh augmentation is used. In comparison, women with uterine prolapse who choose hysterectomy will have a lower risk of uterine and cervical cancer or any procedures that involve abnormalities of the cervix or uterus (eg, endometrial biopsy). They will not become pregnant and will not have uterine bleeding or pain.

Outcome data comparing hysterectomy with hysteropexy are not clear. In one study, vaginal hysterectomy for the treatment of stage II or greater POP was associated with a lower risk of recurrent prolapse than hysteropexy (100). However, in a randomized trial that compared sacrospinous hysteropexy with vaginal hysterectomy and uterosacral ligament vaginal vault suspension for stage 2 or greater POP, sacrospinous hysteropexy was found to be noninferior to vaginal hysterectomy (for anatomic recurrence of the apical compartment with bothersome bulge symptoms or repeat surgery for recurrent apical prolapse): sacrospinous hysteropexy 0% (n=0) versus vaginal hysterectomy 4.0% (n=4), a difference of -3.9% (95% CI, -8.6%–0.7%) over 12 months (102). Longer-term follow-up on this cohort of women is needed. Another study that compared postoperative sexual function in women who underwent hysteropexy with women who underwent hysterectomy found no significant difference between the two groups (98). There is little information regarding pregnancy after uterine suspension (103).

Le Fort Colpocleisis

In women with POP who want to avoid hysterectomy or who have significant comorbidities and no longer desire vaginal coital function, a Le Fort colpocleisis is a therapeutic option. This is an effective treatment for POP with a high success rate and high patient satisfaction. However, patients should be counseled that this surgery is irreversible (77). For more information, see *Are surgical approaches available to treat pelvic organ prolapse in women with medical comorbidities?*

► ***Can the occurrence of stress urinary incontinence after surgery for pelvic organ prolapse be anticipated and avoided?***

All women with significant apical prolapse, anterior prolapse, or both should have a preoperative evaluation



for occult stress urinary incontinence, with cough stress testing or urodynamic testing with the prolapse reduced (104). Some women will have a positive cough stress test result only when their POP is in the reduced position. Prolapse may obstruct the urethra or the urethra might kink from an anterior vaginal wall prolapse. This could mask stress urinary incontinence, which then may present after surgery. In women with bothersome POP and current stress urinary incontinence symptoms, it is prudent to correct both disorders to reduce persistent or worsening stress incontinence after surgery. Because there is no single procedure that adequately treats POP and urinary incontinence, two procedures are done concomitantly. Thus, women with bothersome stress urinary incontinence who are undergoing POP surgery should consider having concomitant treatment for both disorders. The type of continence procedure often is selected based on the route of access for the prolapse repair (104).

Patients with POP but without stress urinary incontinence who are undergoing either abdominal or vaginal prolapse repair should be counseled that postoperative stress urinary incontinence is more likely without a concomitant continence procedure but that the risk of adverse effects is increased with an additional procedure (104). Burch colposuspension at the time of abdominal sacrocolpopexy and retropubic midurethral sling at the time of vaginal surgery for POP repair decrease the risk of postoperative stress urinary incontinence in women without preoperative stress urinary incontinence (104–106). In the CARE trial, women with no reported preoperative stress urinary incontinence who were undergoing open abdominal sacrocolpopexy for prolapse repair were randomized to receive concomitant Burch colposuspension or no continence procedure (105). Fewer women who underwent concomitant Burch colposuspension had postoperative stress incontinence compared with those who underwent sacrocolpopexy alone (34% versus 57%, $P < .001$). Similar results were found in the outcomes after the Vaginal Prolapse Repair and Midurethral Sling trial, which evaluated placement of a prophylactic midurethral sling at the time of vaginal prolapse surgery (106). Among the women who underwent prophylactic midurethral sling placement at the time of vaginal surgery, 24% developed stress urinary incontinence after surgery, compared with 49% in those who underwent only POP surgery.

In women undergoing vaginal POP surgery, the risks of complications from the stress urinary incontinence surgery should be weighed against the risk of postoperative stress urinary incontinence. Some practitioners favor a staged approach in which women undergo stress urinary incontinence surgery after POP surgery only if they develop stress urinary incontinence.

For more information, see Practice Bulletin No. 155, *Urinary Incontinence in Women* (104).

► **What are the complications of pelvic organ prolapse surgery, and how are they managed?**

Complications after native tissue POP surgery include bleeding, infection (typically urinary tract) and voiding dysfunction (which usually is transient). Less common complications include rectovaginal or vesicovaginal fistula, ureteral injury, foreshortened vagina, or a restriction of the vaginal caliber (21, 75). In the Operations and Pelvic Muscle Training in the Management of Apical Support Loss trial, dyspareunia was noted in 16% of women 24 months after native tissue POP surgery (107). Changes in vaginal anatomy may lead to pelvic pain and pain with intercourse. Fistula and ureteral injury require prompt referral to specialists with expertise in managing these conditions. A short vagina or vaginal constriction after POP surgery often can be managed with vaginal estrogen and progressive dilators (108). If these management methods are not successful, referral to a specialist who is experienced with surgical correction of postoperative POP complications is recommended.

There are unique complications associated with synthetic mesh when they are used in POP surgery. These include mesh contracture and erosion into the vagina, urethra, bladder, and rectum. The rate of mesh erosion is approximately 12% after vaginal mesh prolapse surgery (41). When mesh is used for anterior vaginal wall prolapse repair, there is a 10% risk of mesh extrusion, with 6% of these cases requiring surgical correction (88). The rate of dyspareunia is approximately 9% after vaginal mesh prolapse surgery (109). Multiple procedures often are required to manage mesh-related complications (110). Referral to an obstetrician–gynecologist with appropriate training and experience, such as a female pelvic medicine and reconstructive surgery specialist, is recommended for surgical treatment of prolapse mesh complications. For more information, see Committee Opinion No. 694, *Management of Mesh and Graft Complications in Gynecologic Surgery*.

► **How should recurrent pelvic organ prolapse be managed?**

Recurrence of POP is possible after any POP surgery. Recurrence rates between 6% and 30% have been reported (19). Women should be counseled about the risk of recurrence before undergoing POP surgery.

Women who present with recurrent POP should undergo counseling similar to that for women who present with primary POP. It is helpful to review the preoperative examination results and prior surgical reports.



Many patients may choose not to undergo a repeat surgery. They may choose instead to monitor the prolapse or to use a pessary.

If a patient chooses to undergo surgery for recurrent vaginal apex prolapse, abdominal sacrocolpopexy, vaginal colpopexy with possible mesh or graft augmentation, or colpocleisis may be considered if the patient has failed a vaginal native tissue apical suspension. If the surgeon is not comfortable performing these procedures, referral of the patient to a surgeon who subspecializes in pelvic reconstructive surgery and can offer these procedures is recommended.

Summary of Recommendations and Conclusions

The following recommendations and conclusions are based on good and consistent scientific evidence (Level A):

- ▶ Uterosacral and sacrospinous ligament suspension for apical POP with native tissue are equally effective surgical treatments of POP, with comparable anatomic, functional, and adverse outcomes.
- ▶ The use of synthetic mesh or biologic grafts in transvaginal repair of posterior vaginal wall prolapse does not improve outcomes.
- ▶ Polypropylene mesh augmentation of anterior vaginal wall prolapse repair improves anatomic and some subjective outcomes but does not affect reoperation rates for recurrent prolapse and is associated with a higher rate of complications compared with native tissue vaginal prolapse repair.

The following recommendations and conclusions are based on limited or inconsistent scientific evidence (Level B):

- ▶ Many women with POP on physical examination do not report symptoms of POP. Treatment is indicated only if prolapse is causing bothersome bulge and pressure symptoms, sexual dysfunction, lower urinary tract dysfunction, or defecatory dysfunction.
- ▶ Women considering treatment of POP should be offered a vaginal pessary as an alternative to surgery.
- ▶ Vaginal apex suspension should be performed at the time of hysterectomy for uterine prolapse to reduce the risk of recurrent POP.
- ▶ Abdominal sacrocolpopexy with synthetic mesh has a lower risk of recurrent POP but is associated with

more complications than vaginal apex repair with native tissue.

- ▶ Obliterative procedures—which narrow, shorten, or completely close the vagina—are effective for the treatment of POP and should be considered a first-line surgical treatment for women with significant medical comorbidities who do not desire future vaginal intercourse or vaginal preservation.
- ▶ The use of synthetic mesh or biologic grafts in POP surgery is associated with unique complications not seen in POP repair with native tissue.
- ▶ Hysteropexy is a viable alternative to hysterectomy in women with uterine prolapse, although there is less available evidence on safety and efficacy compared with hysterectomy.

The following recommendations are based primarily on consensus and expert opinion (Level C):

- ▶ A POP-Q examination is recommended before treatment for the objective evaluation and documentation of the extent of prolapse.
- ▶ A pessary should be considered for a woman with symptomatic POP who wishes to become pregnant in the future.
- ▶ Pelvic organ prolapse vaginal mesh repair should be limited to high-risk individuals in whom the benefit of mesh placement may justify the risk, such as individuals with recurrent prolapse (particularly of the anterior or apical compartments) or with medical comorbidities that preclude more invasive and lengthier open and endoscopic procedures. Before placement of synthetic mesh grafts in the anterior vaginal wall, patients should provide their informed consent after reviewing the benefits and risks of the procedure and discussing alternative repairs.
- ▶ Surgeons who perform POP surgery with biologic grafts or synthetic mesh grafts should have training specifically for these procedures and should be able to counsel patients regarding the risk–benefit ratio for the use of mesh compared with native tissue repair.
- ▶ Routine intraoperative cystoscopy during POP surgery is recommended when the surgical procedure performed is associated with a significant risk of injury to the bladder or ureter. These procedures include suspension of the vaginal apex to the uterosacral ligaments, sacrocolpopexy, and anterior colporrhaphy and the placement of mesh in the anterior and apical compartments.



- ▶ All women with significant apical prolapse, anterior prolapse, or both should have a preoperative evaluation for occult stress urinary incontinence, with cough stress testing or urodynamic testing with the prolapse reduced.
- ▶ Patients with POP but without stress urinary incontinence who are undergoing either abdominal or vaginal prolapse repair should be counseled that postoperative stress urinary incontinence is more likely without a concomitant continence procedure but that the risk of adverse effects is increased with an additional procedure.

References

1. Wu JM, Matthews CA, Conover MM, Pate V, Jonsson Funk M. Lifetime risk of stress urinary incontinence or pelvic organ prolapse surgery. *Obstet Gynecol* 2014;123:1201–6. (Level II-3) [PubMed] [Full Text] ⇐
2. Luber KM, Boero S, Choe JY. The demographics of pelvic floor disorders: current observations and future projections. *Am J Obstet Gynecol* 2001;184:1496–501; discussion 1501–3. (Level II-3) [PubMed] ⇐
3. Wu JM, Vaughan CP, Goode PS, Redden DT, Burgio KL, Richter HE, et al. Prevalence and trends of symptomatic pelvic floor disorders in U.S. women. *Obstet Gynecol* 2014;123:141–8. (Level II-3) [PubMed] [*Obstetrics & Gynecology*] ⇐
4. Haylen BT, de Ridder D, Freeman RM, Swift SE, Berghmans B, Lee J, et al. An International Urogynecological Association (IUGA)/International Continence Society (ICS) joint report on the terminology for female pelvic floor dysfunction. International Urogynecological Association, International Continence Society. *Neurourol Urodyn* 2010;29:4–20. (Level III) [PubMed] [Full Text] ⇐
5. Gutman RE, Ford DE, Quiroz LH, Shippey SH, Handa VL. Is there a pelvic organ prolapse threshold that predicts pelvic floor symptoms? *Am J Obstet Gynecol* 2008;199:683.e1–7. (Level II-3) [PubMed] [Full Text] ⇐
6. Barber MD, Maher C. Epidemiology and outcome assessment of pelvic organ prolapse. *Int Urogynecol J* 2013;24:1783–90. (Level III) [PubMed] ⇐
7. Swift S, Woodman P, O'Boyle A, Kahn M, Valley M, Bland D, et al. Pelvic Organ Support Study (POSST): the distribution, clinical definition, and epidemiologic condition of pelvic organ support defects. *Am J Obstet Gynecol* 2005;192:795–806. (Level II-3) [PubMed] ⇐
8. Gilchrist AS, Campbell W, Steele H, Brazell H, Foote J, Swift S. Outcomes of observation as therapy for pelvic organ prolapse: a study in the natural history of pelvic organ prolapse. *Neurourol Urodyn* 2013;32:383–6. (Level II-3) [PubMed] ⇐
9. Bradley CS, Zimmerman MB, Qi Y, Nygaard IE. Natural history of pelvic organ prolapse in postmenopausal women. *Obstet Gynecol* 2007;109:848–54. (Level II-3) [PubMed] [*Obstetrics & Gynecology*] ⇐
10. Boyles SH, Weber AM, Meyn L. Procedures for pelvic organ prolapse in the United States, 1979–1997. *Am J Obstet Gynecol* 2003;188:108–15. (Level II-3) [PubMed] ⇐
11. Shah AD, Kohli N, Rajan SS, Hoyte L. The age distribution, rates, and types of surgery for pelvic organ prolapse in the USA. *Int Urogynecol J Pelvic Floor Dysfunct* 2008;19:421–8. (Level II-3) [PubMed] ⇐
12. Smith FJ, Holman CD, Moorin RE, Tsokos N. Lifetime risk of undergoing surgery for pelvic organ prolapse. *Obstet Gynecol* 2010;116:1096–100. (Level II-3) [PubMed] [*Obstetrics & Gynecology*] ⇐
13. Mant J, Painter R, Vessey M. Epidemiology of genital prolapse: observations from the Oxford Family Planning Association Study. *Br J Obstet Gynaecol* 1997;104:579–85. (Level II-3) [PubMed] ⇐
14. Maher C, Baessler K. Surgical management of posterior vaginal wall prolapse: an evidence-based literature review. *Int Urogynecol J Pelvic Floor Dysfunct* 2006;17:84–8. (Level III) [PubMed] ⇐
15. Weber AM, Richter HE. Pelvic organ prolapse. *Obstet Gynecol* 2005;106:615–34. (Level III) [PubMed] [*Obstetrics & Gynecology*] ⇐
16. Handa VL, Blomquist JL, Knoepp LR, Hoskey KA, McDermott KC, Munoz A. Pelvic floor disorders 5–10 years after vaginal or cesarean childbirth. *Obstet Gynecol* 2011;118:777–84. (Level II-2) [PubMed] [*Obstetrics & Gynecology*] ⇐
17. Vergeldt TF, Weemhoff M, IntHout J, Kluivers KB. Risk factors for pelvic organ prolapse and its recurrence: a systematic review. *Int Urogynecol J* 2015;26:1559–73. (Systematic review) [PubMed] [Full Text] ⇐
18. Blandon RE, Bharucha AE, Melton LJ 3rd, Schleck CD, Babalola EO, Zinsmeister AR, et al. Incidence of pelvic floor repair after hysterectomy: A population-based cohort study. *Am J Obstet Gynecol* 2007;197:664.e1–7. (Level II-3) [PubMed] [Full Text] ⇐
19. Dällenbach P. To mesh or not to mesh: a review of pelvic organ reconstructive surgery. *Int J Womens Health* 2015;7:331–43. (Level III) [PubMed] [Full Text] ⇐
20. Nygaard I, Brubaker L, Zyczynski HM, Cundiff G, Richter H, Gantz M, et al. Long-term outcomes following abdominal sacrocolpopexy for pelvic organ prolapse [published erratum appears in *JAMA* 2013;310:1076]. *JAMA* 2013;309:2016–24. (Level I) [PubMed] [Full Text] ⇐
21. Barber MD, Brubaker L, Burgio KL, Richter HE, Nygaard I, Weidner AC, et al. Comparison of 2 transvaginal surgical approaches and perioperative behavioral therapy for apical vaginal prolapse: the OPTIMAL randomized trial. Eunice Kennedy Shriver National Institute of Child Health and Human Development Pelvic Floor Disorders Network [published erratum appears in *JAMA* 2015;313:2287]. *JAMA* 2014;311:1023–34. (Level I) [PubMed] [Full Text] ⇐
22. Larson KA, Smith T, Berger MB, Abernethy M, Mead S, Fenner DE, et al. Long-term patient satisfaction with Michigan four-wall sacrospinous ligament suspension



- for prolapse. *Obstet Gynecol* 2013;122:967–75. (Level II-3) [PubMed] [*Obstetrics & Gynecology*] ↵
23. Eilber KS, Alperin M, Khan A, Wu N, Pashos CL, Clemens JQ, et al. Outcomes of vaginal prolapse surgery among female Medicare beneficiaries: the role of apical support. *Obstet Gynecol* 2013;122:981–7. (Level II-3) [PubMed] [*Obstetrics & Gynecology*] ↵
 24. Whiteside JL, Weber AM, Meyn LA, Walters MD. Risk factors for prolapse recurrence after vaginal repair. *Am J Obstet Gynecol* 2004;191:1533–8. (Level II-3) [PubMed] ↵
 25. Nieminen K, Huhtala H, Heinonen PK. Anatomic and functional assessment and risk factors of recurrent prolapse after vaginal sacrospinous fixation. *Acta Obstet Gynecol Scand* 2003;82:471–8. (Level II-3) [PubMed] [Full Text] ↵
 26. Diez-Itza I, Aizpitarte I, Becerro A. Risk factors for the recurrence of pelvic organ prolapse after vaginal surgery: a review at 5 years after surgery. *Int Urogynecol J Pelvic Floor Dysfunct* 2007;18:1317–24. (Level II-3) [PubMed] ↵
 27. Abrams P, Andersson KE, Birder L, Brubaker L, Cardozo L, Chapple C, et al. Fourth International Consultation on Incontinence recommendations of the International Scientific Committee: evaluation and treatment of urinary incontinence, pelvic organ prolapse, and fecal incontinence. *Neurourol Urodyn* 2010;29:213–40. (Level III) [PubMed] [Full Text] ↵
 28. Bump RC, Mattiasson A, Bo K, Brubaker LP, DeLancey JO, Klarskov P, et al. The standardization of terminology of female pelvic organ prolapse and pelvic floor dysfunction. *Am J Obstet Gynecol* 1996;175:10–7. (Level III) [PubMed] ↵
 29. Hall AF, Theofrastous JP, Cundiff GW, Harris RL, Hamilton LF, Swift SE, et al. Interobserver and intraobserver reliability of the proposed International Continence Society, Society of Gynecologic Surgeons, and American Urogynecologic Society pelvic organ prolapse classification system. *Am J Obstet Gynecol* 1996;175:1467–70; discussion 1470–1. (Level II-3) [PubMed] ↵
 30. Kobak WH, Rosenberger K, Walters MD. Interobserver variation in the assessment of pelvic organ prolapse. *Int Urogynecol J Pelvic Floor Dysfunct* 1996;7:121–4. (Level II-2) [PubMed] ↵
 31. Pham T, Burgart A, Kenton K, Mueller ER, Brubaker L. Current use of pelvic organ prolapse quantification by AUGS and ICS members. *Female Pelvic Med Reconstr Surg* 2011;17:67–9. (Level III) ↵
 32. Treszezamsky AD, Rascoff L, Shahryarinejad A, Vardy MD. Use of pelvic organ prolapse staging systems in published articles of selected specialized journals. *Int Urogynecol J* 2010;21:359–63. (Level III) [PubMed] ↵
 33. Spiller RC, Thompson WG. Bowel disorders. *Am J Gastroenterol* 2010;105:775–85. (Level III) [PubMed] ↵
 34. Braekken IH, Majida M, Engh ME, Bo K. Can pelvic floor muscle training reverse pelvic organ prolapse and reduce prolapse symptoms? An assessor-blinded, randomized, controlled trial. *Am J Obstet Gynecol* 2010;203:170.e1–7. (Level I) [PubMed] [Full Text] ↵
 35. Hagen S, Stark D. Conservative prevention and management of pelvic organ prolapse in women. *Cochrane Database of Systematic Reviews* 2011, Issue 12. Art. No.: CD003882. (Systematic review) [PubMed] [Full Text] ↵
 36. Ismail SI, Bain C, Hagen S. Oestrogens for treatment or prevention of pelvic organ prolapse in postmenopausal women. *Cochrane Database of Systematic Reviews* 2010, Issue 9. Art. No.: CD007063. (Systematic review) [PubMed] [Full Text] ↵
 37. Cundiff GW, Amundsen CL, Bent AE, Coates KW, Schaffer JJ, Strohbehn K, et al. The PESSRI study: symptom relief outcomes of a randomized crossover trial of the ring and Gellhorn pessaries. *Am J Obstet Gynecol* 2007;196:405.e1–8. (Level II-3) [PubMed] ↵
 38. Clemons JL, Aguilar VC, Tillinghast TA, Jackson ND, Myers DL. Patient satisfaction and changes in prolapse and urinary symptoms in women who were fitted successfully with a pessary for pelvic organ prolapse. *Am J Obstet Gynecol* 2004;190:1025–9. (Level II-3) [PubMed] ↵
 39. Robert M, Schulz JA, Harvey MA, Lovatsis D, Walter JE, Chou Q, et al. Technical update on pessary use. *Urogynaecology Committee. J Obstet Gynaecol Can* 2013;35:664–74. (Level III) [PubMed] [Full Text] ↵
 40. Arias BE, Ridgeway B, Barber MD. Complications of neglected vaginal pessaries: case presentation and literature review. *Int Urogynecol J Pelvic Floor Dysfunct* 2008;19:1173–8. (Level III) [PubMed] ↵
 41. Maher C, Feiner B, Baessler K, Christmann-Schmid C, Haya N, Majoribanks J. Transvaginal mesh or grafts compared with native tissue repair for vaginal prolapse. *Cochrane Database of Systematic Reviews* 2016, Issue 2. Art. No.: CD012079. (Systematic review) [PubMed] ↵
 42. Webb MJ, Aronson MP, Ferguson LK, Lee RA. Posthysterectomy vaginal vault prolapse: primary repair in 693 patients. *Obstet Gynecol* 1998;92:281–5. (Level II-3) [PubMed] ↵
 43. Shull BL, Bachofen C, Coates KW, Kuehl TJ. A transvaginal approach to repair of apical and other associated sites of pelvic organ prolapse with uterosacral ligaments. *Am J Obstet Gynecol* 2000;183:1365–73; discussion 1373–4. (Level II-3) [PubMed] ↵
 44. Cruikshank SH, Kovac SR. Randomized comparison of three surgical methods used at the time of vaginal hysterectomy to prevent posterior enterocele. *Am J Obstet Gynecol* 1999;180:859–65. (Level I) [PubMed] ↵
 45. McCall ML. Posterior culdeplasty; surgical correction of enterocele during vaginal hysterectomy; a preliminary report. *Obstet Gynecol* 1957;10:595–602. (Level III) [PubMed] ↵
 46. Petri E, Ashok K. Sacrospinous vaginal fixation--current status. *Acta Obstet Gynecol Scand* 2011;90:429–36. (Level III) [PubMed] [Full Text] ↵
 47. Chmielewski L, Walters MD, Weber AM, Barber MD. Reanalysis of a randomized trial of 3 techniques of anterior colporrhaphy using clinically relevant definitions of success. *Am J Obstet Gynecol* 2011;205:69.e1–8. (Level I) [PubMed] [Full Text] ↵



48. Chen L, Ashton-Miller JA, Hsu Y, DeLancey JO. Interaction among apical support, levator ani impairment, and anterior vaginal wall prolapse. *Obstet Gynecol* 2006;108:324–32. (Level III) [PubMed] [Full Text] ⇐
49. Richardson AC. The anatomic defects in rectocele techniques and enterocele. *J Pelv Surg* 1995;1:214–21. (Level III) ⇐
50. Larson KA, Luo J, Guire KE, Chen L, Ashton-Miller JA, DeLancey JO. 3D analysis of cystoceles using magnetic resonance imaging assessing midline, paravaginal, and apical defects. *Int Urogynecol J* 2012;23:285–93. (Level II-3) [PubMed] [Full Text] ⇐
51. Barber MD, Cundiff GW, Weidner AC, Coates KW, Bump RC, Addison WA. Accuracy of clinical assessment of paravaginal defects in women with anterior vaginal wall prolapse. *Am J Obstet Gynecol* 1999;181:87–90. (Level III) [PubMed] ⇐
52. Dietz HP, Pang S, Korda A, Beness C. Paravaginal defects: a comparison of clinical examination and 2D/3D ultrasound imaging. *Aust N Z J Obstet Gynaecol* 2005;45:187–90. (Level II-3) [PubMed] [Full Text] ⇐
53. Shippey SH, Quiroz LH, Sanses TV, Knoepp LR, Cundiff GW, Handa VL. Anatomic outcomes of abdominal sacrocolpopexy with or without paravaginal repair. *Int Urogynecol J* 2010;21:279–83. (Level II-3) [PubMed] ⇐
54. Karram M, Maher C. Surgery for posterior vaginal wall prolapse. *Int Urogynecol J* 2013;24:1835–41. (Level III) [PubMed] ⇐
55. Kahn MA, Stanton SL. Posterior colporrhaphy: its effects on bowel and sexual function. *Br J Obstet Gynaecol* 1997;104:82–6. (Level II-3) [PubMed] ⇐
56. Cundiff GW, Weidner AC, Visco AG, Addison WA, Bump RC. An anatomic and functional assessment of the discrete defect rectocele repair. *Am J Obstet Gynecol* 1998;179:1451–6; discussion 1456–7. (Level III) [PubMed] ⇐
57. Abramov Y, Gandhi S, Goldberg RP, Botros SM, Kwon C, Sand PK. Site-specific rectocele repair compared with standard posterior colporrhaphy. *Obstet Gynecol* 2005;105:314–8. (Level II-3) [PubMed] ⇐
58. Paraiso MF, Barber MD, Muir TW, Walters MD. Rectocele repair: a randomized trial of three surgical techniques including graft augmentation. *Am J Obstet Gynecol* 2006;195:1762–71. (Level I) [PubMed] ⇐
59. Maher CF, Qatawneh AM, Dwyer PL, Carey MP, Cornish A, Schluter PJ. Abdominal sacral colpopexy or vaginal sacrospinous colpopexy for vaginal vault prolapse: a prospective randomized study. *Am J Obstet Gynecol* 2004;190:20–6. (Level I) [PubMed] ⇐
60. Culligan PJ, Salamon C, Priestley JL, Shariati A. Porcine dermis compared with polypropylene mesh for laparoscopic sacrocolpopexy: a randomized controlled trial. *Obstet Gynecol* 2013;121:143–51. (Level I) [PubMed] [Obstetrics & Gynecology] ⇐
61. Tate SB, Blackwell L, Lorenz DJ, Steptoe MM, Culligan PJ. Randomized trial of fascia lata and polypropylene mesh for abdominal sacrocolpopexy: 5-year follow-up. *Int Urogynecol J* 2011;22:137–43. (Level I) [PubMed] ⇐
62. Siddiqui NY, Grimes CL, Casiano ER, Abed HT, Jeppson PC, Olivera CK, et al. Mesh sacrocolpopexy compared with native tissue vaginal repair: a systematic review and meta-analysis. Society of Gynecologic Surgeons Systematic Review Group. *Obstet Gynecol* 2015;125:44–55. (Systematic review) [PubMed] [Obstetrics & Gynecology] ⇐
63. Hudson CO, Northington GM, Lyles RH, Karp DR. Outcomes of robotic sacrocolpopexy: a systematic review and meta-analysis. *Female Pelvic Med Reconstr Surg* 2014;20:252–60. (Systematic review) [PubMed] [Full Text] ⇐
64. Nosti PA, Umoh Andy U, Kane S, White DE, Harvie HS, Lowenstein L, et al. Outcomes of abdominal and minimally invasive sacrocolpopexy: a retrospective cohort study. *Female Pelvic Med Reconstr Surg* 2014;20:33–7. (Level II-2) [PubMed] [Full Text] ⇐
65. Freeman RM, Pantazis K, Thomson A, Frappell J, Bombieri L, Moran P, et al. A randomised controlled trial of abdominal versus laparoscopic sacrocolpopexy for the treatment of post-hysterectomy vaginal vault prolapse: LAS study. *Int Urogynecol J* 2013;24:377–84. (Level I) [PubMed] ⇐
66. Tarr ME, Brancato SJ, Cunkelman JA, Polcari A, Nutter B, Kenton K. Comparison of postural ergonomics between laparoscopic and robotic sacrocolpopexy: a pilot study. *J Minim Invasive Gynecol* 2015;22:234–8. (Level II-2) [PubMed] ⇐
67. Diana M, Marescaux J. Robotic surgery. *Br J Surg* 2015;102:e15–28. (Level III) [PubMed] ⇐
68. Awad N, Mustafa S, Amit A, Deutsch M, Eldor-Itskovitz J, Lowenstein L. Implementation of a new procedure: laparoscopic versus robotic sacrocolpopexy. *Arch Gynecol Obstet* 2013;287:1181–6. (Level II-3) [PubMed] ⇐
69. Paraiso MF, Jelovsek JE, Frick A, Chen CC, Barber MD. Laparoscopic compared with robotic sacrocolpopexy for vaginal prolapse: a randomized controlled trial. *Obstet Gynecol* 2011;118:1005–13. (Level I) [PubMed] [Obstetrics & Gynecology] ⇐
70. Seror J, Yates DR, Seringe E, Vaessen C, Bitker MO, Chartier-Kastler E, et al. Prospective comparison of short-term functional outcomes obtained after pure laparoscopic and robot-assisted laparoscopic sacrocolpopexy. *World J Urol* 2012;30:393–8. (Level II-3) [PubMed] ⇐
71. Collins SA, Tulikangas PK, O’Sullivan DM. Effect of surgical approach on physical activity and pain control after sacral colpopexy. *Am J Obstet Gynecol* 2012;206:438.e1–6. (Level II-3) [PubMed] ⇐
72. Anger JT, Mueller ER, Tarnay C, Smith B, Stroupe K, Rosenman A, et al. Robotic compared with laparoscopic sacrocolpopexy: a randomized controlled trial [published erratum appears in *Obstet Gynecol* 2014;124:165]. *Obstet Gynecol* 2014;123:5–12. (Level I) [PubMed] [Obstetrics & Gynecology] ⇐
73. Liu H, Lawrie TA, Lu DH, Song H, Wang L, Shi G. Robot-assisted surgery in gynaecology. *Cochrane*



- Database of Systematic Reviews 2014, Issue 12. Art. No.: CD011422. (Systematic review) [PubMed] [Full Text] ⇐
74. Robotic surgery in gynecology. Committee Opinion No. 628. American College of Obstetricians and Gynecologists. *Obstet Gynecol* 2015;125:760–7. (Level III) [PubMed] [*Obstetrics & Gynecology*] ⇐
 75. Maher C, Feiner B, Baessler K, Schmid C. Surgical management of pelvic organ prolapse in women. Cochrane Database of Systematic Reviews 2013, Issue 4. Art. No.: CD004014. (Systematic review) [PubMed] [Full Text] ⇐
 76. Sung VW, Weitzen S, Sokol ER, Rardin CR, Myers DL. Effect of patient age on increasing morbidity and mortality following urogynecologic surgery. *Am J Obstet Gynecol* 2006;194:1411–7. (Level II-3) [PubMed] ⇐
 77. FitzGerald MP, Richter HE, Siddique S, Thompson P, Zyczynski H, Weber A. Colpocleisis: a review. Pelvic Floor Disorders Network. *Int Urogynecol J Pelvic Floor Dysfunct* 2006;17:261–71. (Level III) [PubMed] ⇐
 78. Barber MD, Amundsen CL, Paraiso MF, Weidner AC, Romero A, Walters MD. Quality of life after surgery for genital prolapse in elderly women: obliterative and reconstructive surgery. *Int Urogynecol J Pelvic Floor Dysfunct* 2007;18:799–806. (Level II-3) [PubMed] ⇐
 79. Fitzgerald MP, Richter HE, Bradley CS, Ye W, Visco AC, Cundiff GW, et al. Pelvic support, pelvic symptoms, and patient satisfaction after colpocleisis. Pelvic Floor Disorders Network. *Int Urogynecol J Pelvic Floor Dysfunct* 2008;19:1603–9. (Level II-3) [PubMed] [Full Text] ⇐
 80. von Pechmann WS, Mutone M, Fyffe J, Hale DS. Total colpocleisis with high levator plication for the treatment of advanced pelvic organ prolapse. *Am J Obstet Gynecol* 2003;189:121–6. (Level II-3) [PubMed] ⇐
 81. Wheeler TL 2nd, Richter HE, Burgio KL, Redden DT, Chen CC, Goode PS, et al. Regret, satisfaction, and symptom improvement: analysis of the impact of partial colpocleisis for the management of severe pelvic organ prolapse. *Am J Obstet Gynecol* 2005;193:2067–70. (Level III) [PubMed] ⇐
 82. Mueller MG, Ellimootil C, Abernethy MG, Mueller ER, Hohmann S, Kenton K. Colpocleisis: a safe, minimally invasive option for pelvic organ prolapse. *Female Pelvic Med Reconstr Surg* 2015;21:30–3. (Level II-2) [PubMed] [Full Text] ⇐
 83. Glavind K, Kempf L. Colpectomy or Le Fort colpocleisis—a good option in selected elderly patients. *Int Urogynecol J Pelvic Floor Dysfunct* 2005;16:48–51; discussion 51. (Level II-2) [PubMed] ⇐
 84. Food and Drug Administration. Urogynecologic surgical mesh: update on the safety and effectiveness of transvaginal placement for pelvic organ prolapse. Silver Spring (MD): FDA; 2011. Available at: <http://www.fda.gov/downloads/medicaldevices/safety/alertsandnotices/UCM262760.pdf>. Retrieved October 17, 2016. (Level III) [PubMed] [Full Text] ⇐
 85. Surgical mesh for transvaginal pelvic organ prolapse repair. 21 C.F.R. § 884.5980 (2016) (Level III) ⇐
 86. Obstetrical and gynecological devices; reclassification of surgical instrumentation for use with urogynecologic surgical mesh. *Fed Regist* 2017;82:1598–603. (Level III) [PubMed] ⇐
 87. Sung VW, Rardin CR, Raker CA, Lasala CA, Myers DL. Porcine subintestinal submucosal graft augmentation for rectocele repair: a randomized controlled trial. *Obstet Gynecol* 2012;119:125–33. (Level I) [PubMed] [*Obstetrics & Gynecology*] ⇐
 88. Maher C. Anterior vaginal compartment surgery. *Int Urogynecol J* 2013;24:1791–802. (Level III) [PubMed] ⇐
 89. Sung VW, Rogers RG, Schaffer JI, Balk EM, Uhlig K, Lau J, et al. Graft use in transvaginal pelvic organ prolapse repair: a systematic review. Society of Gynecologic Surgeons Systematic Review Group. *Obstet Gynecol* 2008;112:1131–42. (Systematic review) [PubMed] [Full Text] ⇐
 90. Ellington DR, Richter HE. Indications, contraindications, and complications of mesh in surgical treatment of pelvic organ prolapse. *Clin Obstet Gynecol* 2013;56:276–88. (Level III) [PubMed] [Full Text] ⇐
 91. de Tayrac R, Faillie JL, Gaillet S, Boileau L, Triopon G, Letouzey V. Analysis of the learning curve of bilateral anterior sacrospinous ligament suspension associated with anterior mesh repair. *Eur J Obstet Gynecol Reprod Biol* 2012;165:361–5. (Level II-3) [PubMed] ⇐
 92. Guidelines for providing privileges and credentials to physicians for transvaginal placement of surgical mesh for pelvic organ prolapse. American Urogynecologic Society’s Guidelines Development Committee. *Female Pelvic Med Reconstr Surg* 2012;18:194–7. (Level III) [PubMed] [Full Text] ⇐
 93. Guidelines for privileging and credentialing physicians for sacrocolpopexy for pelvic organ prolapse. American Urogynecologic Society’s Guidelines Development Committee. *Female Pelvic Med Reconstr Surg* 2013;19:62–5. (Level III) [PubMed] ⇐
 94. Brubaker L, Cundiff G, Fine P, Nygaard I, Richter H, Visco A, et al. A randomized trial of colpopexy and urinary reduction efforts (CARE): design and methods. Pelvic Floor Disorders Network. *Control Clin Trials* 2003;24:629–42. (Level I) [PubMed] ⇐
 95. Barber MD, Brubaker L, Menefee S, Norton P, Borello-France D, Varner E, et al. Operations and pelvic muscle training in the management of apical support loss (OPTIMAL) trial: design and methods. Pelvic Floor Disorders Network. *Contemp Clin Trials* 2009;30:178–89. (Level I) [PubMed] [Full Text] ⇐
 96. Kwon CH, Goldberg RP, Koduri S, Sand PK. The use of intraoperative cystoscopy in major vaginal and urogynecologic surgeries. *Am J Obstet Gynecol* 2002;187:1466–71; discussion 1471–2. (Level II-3) [PubMed] [Full Text] ⇐
 97. Korbly NB, Kassis NC, Good MM, Richardson ML, Book NM, Yip S, et al. Patient preferences for uterine preservation and hysterectomy in women with pelvic organ prolapse. *Am J Obstet Gynecol* 2013;209:470.e1–6. (Level II-3) [PubMed] [Full Text] ⇐



98. Jeng CJ, Yang YC, Tzeng CR, Shen J, Wang LR. Sexual functioning after vaginal hysterectomy or transvaginal sacrospinous uterine suspension for uterine prolapse: a comparison. *J Reprod Med* 2005;50:669–74. (Level II-3) [PubMed] ↵
99. Gutman R, Maher C. Uterine-preserving POP surgery. *Int Urogynecol J* 2013;24:1803–13. (Level III) [PubMed] ↵
100. Dietz V, van der Vaart CH, van der Graaf Y, Heintz P, Schraffordt Koops SE. One-year follow-up after sacrospinous hysteropexy and vaginal hysterectomy for uterine descent: a randomized study. *Int Urogynecol J* 2010;21:209–16. (Level I) [PubMed] [Full Text] ↵
101. Gutman RE, Rardin CR, Sokol ER, Matthews C, Park AJ, Iglesia CB, et al. Vaginal and laparoscopic mesh hysteropexy for uterovaginal prolapse: a parallel cohort study. *Am J Obstet Gynecol* 2017;216:38.e1–38. (Level II-2) [PubMed] [Full Text] ↵
102. Detollenaere RJ, den Boon J, Stekelenburg J, IntHout J, Vierhout ME, Kluivers KB, et al. Sacrospinous hysteropexy versus vaginal hysterectomy with suspension of the uterosacral ligaments in women with uterine prolapse stage 2 or higher: multicentre randomised non-inferiority trial. *BMJ* 2015;351:h3717. (Level I) [PubMed] [Full Text] ↵
103. Kovac SR, Cruikshank SH. Successful pregnancies and vaginal deliveries after sacrospinous uterosacral fixation in five of nineteen patients. *Am J Obstet Gynecol* 1993;168:1778–83; discussion 1783–6. (Level III) [PubMed] ↵
104. Urinary incontinence in women. Practice Bulletin No. 155. American College of Obstetricians and Gynecologists. *Obstet Gynecol* 2015;126:e66–81. (Level III) [PubMed] [*Obstetrics & Gynecology*] ↵
105. Brubaker L, Nygaard I, Richter HE, Visco A, Weber AM, Cundiff GW, et al. Two-year outcomes after sacrocolpopexy with and without Burch to prevent stress urinary incontinence. *Obstet Gynecol* 2008;112:49–55. (Level I) [PubMed] [*Obstetrics & Gynecology*] ↵
106. Wei JT, Nygaard I, Richter HE, Nager CW, Barber MD, Kenton K, et al. A midurethral sling to reduce incontinence after vaginal prolapse repair. *Pelvic Floor Disorders Network*. *N Engl J Med* 2012;366:2358–67. (Level I) [PubMed] [Full Text] ↵
107. Lukacz ES, Warren LK, Richter HE, Brubaker L, Barber MD, Norton P, et al. Quality of life and sexual function 2 years after vaginal surgery for prolapse. *Obstet Gynecol* 2016;127:1071–9. (Level I) [PubMed] [*Obstetrics & Gynecology*] ↵
108. Antosh DD, Gutman RE, Park AJ, Sokol AI, Peterson JL, Kingsberg SA, et al. Vaginal dilators for prevention of dyspareunia after prolapse surgery: a randomized controlled trial. *Obstet Gynecol* 2013;121:1273–80. (Level I) [PubMed] [*Obstetrics & Gynecology*] ↵
109. Abed H, Rahn DD, Lowenstein L, Balk EM, Clemons JL, Rogers RG. Incidence and management of graft erosion, wound granulation, and dyspareunia following vaginal prolapse repair with graft materials: a systematic review. Systematic Review Group of the Society of Gynecologic Surgeons. *Int Urogynecol J* 2011;22:789–98. (Systematic review) [PubMed] ↵
110. Margulies RU, Lewicky-Gaupp C, Fenner DE, McGuire EJ, Clemens JQ, Delancey JO. Complications requiring reoperation following vaginal mesh kit procedures for prolapse. *Am J Obstet Gynecol* 2008;199:678.e1–4. (Level III) [PubMed] [Full Text] ↵



The MEDLINE database, the Cochrane Library, and ACOG's own internal resources and documents were used to conduct a literature search to locate relevant articles published between January 2000 and October 2016. The search was restricted to articles published in the English language. Priority was given to articles reporting results of original research, although review articles and commentaries also were consulted. Abstracts of research presented at symposia and scientific conferences were not considered adequate for inclusion in this document. Guidelines published by organizations or institutions such as the National Institutes of Health and the American College of Obstetricians and Gynecologists were reviewed, and additional studies were located by reviewing bibliographies of identified articles. When reliable research was not available, expert opinions from obstetrician-gynecologists were used.

Studies were reviewed and evaluated for quality according to the method outlined by the U.S. Preventive Services Task Force:

- I Evidence obtained from at least one properly designed randomized controlled trial.
- II-1 Evidence obtained from well-designed controlled trials without randomization.
- II-2 Evidence obtained from well-designed cohort or case-control analytic studies, preferably from more than one center or research group.
- II-3 Evidence obtained from multiple time series with or without the intervention. Dramatic results in uncontrolled experiments also could be regarded as this type of evidence.
- III Opinions of respected authorities, based on clinical experience, descriptive studies, or reports of expert committees.

Based on the highest level of evidence found in the data, recommendations are provided and graded according to the following categories:

Level A—Recommendations are based on good and consistent scientific evidence.

Level B—Recommendations are based on limited or inconsistent scientific evidence.

Level C—Recommendations are based primarily on consensus and expert opinion.

Full-text document published concurrently in the April 2017 issue of *Female Pelvic Medicine & Reconstructive Surgery*.

Copyright April 2017 by the American College of Obstetricians and Gynecologists. All rights reserved. No part of this publication may be reproduced, stored in a retrieval system, posted on the Internet, or transmitted, in any form or by any means, electronic, mechanical, photocopying, recording, or otherwise, without prior written permission from the publisher.

Requests for authorization to make photocopies should be directed to Copyright Clearance Center, 222 Rosewood Drive, Danvers, MA 01923, (978) 750-8400.

The American College of Obstetricians and Gynecologists
409 12th Street, SW, PO Box 96920, Washington, DC 20090-6920

Pelvic organ prolapse. Practice Bulletin No. 176. American College of Obstetricians and Gynecologists. *Obstet Gynecol* 2017;129:e56-72.

